




BONE AGE ESTIMATION OF THE RADIAL UPPER END OF FEMALE SUDANESE POPULATION

FAIZ YOUSIF MOHAMMED^{1*}, ABBAS A.A.¹, A.KHALIL², ABUBAKER ELSIDDIG TALHA³,
YASIR HAKIM⁴ HIND MUSTAFA⁵

¹⁻⁵Department of Basic medical science, College of Medicine, Dar Al Uloom University,
Riyadh, Kingdom of Saudi Arabia.

Correspondence Author: asadadam@live.com



ABSTRACT

The main objective of this research is to estimate the bone age of the upper end of the radius at the elbow joint by using radiographs of female Sudanese population, To determine the problems a child might be prone to develop, To determine the time of appearance and fusion of ossification centers of upper end of the radius. To know the relation between the estimation of the different age of bones of the elbow. X-rays images of the upper end of the radius at the elbow joint in the supine position. X-rays were taken by Shimadzu x-ray system and Toshiba All the samples were already complaining of upper limb pain and were referred to X- ray department. The numbers of the radiographs were 40, 35 of them were suitable for analysis, while 5 were excluded due to different pathological and congenital causes. The data were classified into four age groups according to stage of ossification of O.Cs. The study showed that the ossification center of the upper end of the radius appears during the fifth year in female and it joined the shaft during the fifteenth years in female. Generally the ossification centers of the bones around the elbow joint in Sudanese children is similar to that of Schinizand Baenisch particularly in the upper end of radius, lateral epicondyle and olecranon process but there is slight difference in capitulum and great difference in the medial epicondyle.

Key words: Radius, Elbow joint, Ossification, X- ray.

©KY PUBLICATIONS

INTRODUCTION

Bone age estimation is one of the important applications radiography especially for the diagnosis of endocrinological problems and growth disorders in children. BA estimation (BAE) is tedious, time-consuming and highly dependent upon the expert experience. Nowadays, most BAE standards are based on American standards. The estimation of bone age plays an important role in diagnostic and therapeutic investigations of endocrine problems and growth disorders of children. The most commonly used method in the United States is the Greulich and Pyle (G&P) Hand Atlas, unchanged from its initial publication in 1950s. In addition, it was exclusively based on the Caucasian population and may not be fully applicable to the other racial descendants of today. Estimation of skeletal age using radiographic images is widely used in assessing biological growth in

clinical and auxological studies. The most frequently used areas for age estimation in children and adolescents are tooth and wrist/hand, both giving good results with only a low level of radiation. Clinical assessment of skeletal maturity is based on a visual comparison of a left-hand wrist radiograph with atlas patterns. Using a new digital hand atlas an image analysis methodology is being developed. To assist radiologists in bone age estimation. The bone age study can help evaluate how fast or slowly a child's skeleton is maturing, which can help doctors diagnose conditions that delay or accelerate growth. Bone age can be used to predict how much a child is growing and when a child will enter puberty⁽³⁾ Estimation of bone age is very important in medico-legal science and serves as a very reliable evidence for age determination a person during marriages and fixation of criminal responsibility. This comparative study to estimate age of upper end of the upper end of the radius in female Sudanese children and adolescents aged between 1 and 19 years, the children were from all social classes.

Justification: Bone age estimation is the important applications of pediatric radiography, especially for the diagnosis of endocrinological problems and growth disorders. The bone age study can help evaluate how fast or slowly a child's skeleton is maturing, which can help doctors diagnose conditions that delay or accelerate growth.

Bone age can be used to predict:

- how much the Sudanese girls is growing
- when the Sudanese girls will enter puberty

Objectives

General Objective: To estimate the bone age of the upper end of the radius at the elbow joint by using radiographs of female Sudanese population.

Specific Objectives

1. To determine the problems a child might be prone to develop.
2. To determine the time of appearance and fusion of ossification centers of upper end of the radius.
3. To know the relation between the estimation of the different age of bones of the elbow.

Literature Review

Skeletal Maturity: From the moment you are born until the time you're grown up, your bones go through a set of characteristic changes. Therefore the skeletal maturity, or bone age, can be estimated from radiographs of specific bones in the human body. Children who grow exceptionally slow or fast are often examined by making a radiograph of their left hand and wrist. From the radiograph, the bone age can be estimated. From this estimate, together with other pieces of information such as the calendar age, sex and height of the child and possibly information about the parents, the adult height can be predicted. A big discrepancy between the calendar age and the bone age can indicate an atypical skeletal development. In many cases the decision whether to treat a child with growth hormones depends on the outcome of bone age estimation. The image is compared with reference photographs in an atlas. In this way the skeletal maturity of several bones is determined.⁽¹⁾ A child's bones contain growing zones at both ends called "growth plates" include special cells responsible for the bones growth in length, these plates are easy to spot on an x-ray because they are softer and contain less minerals. Growth plates on the x-ray appear thinner and eventually disappearing, after epiphysis has fused to the shaft the ski gram shows a line of greater density along the epiphysis called epiphyseal scars, lies interior rather than an epiphyseal line. Bone age based on the appearance of the bones and growth plates. At birth, only the metaphases of the "long bone" are present. The long bones are those that grow primarily by elongation at an epiphysis at one end of the growing bone. The long bones include the femurs, tibias, and fibulas of the lower limb, the humeri, radii, and ulnas of the upper limb (arm + forearm), and the phalanges of the fingers and toes.⁽²⁾ Longitudinal growth in long bones of extremities occurs through the process of endochondral ossification. In contrast the width of the bone increased by thickness of the skin. As a child grows the epiphyses become calcified and appear on the x-rays, as do the carpal and tarsal bones of the hands and feet, separated on the x-rays by a layer of invisible cartilage where most of the growth is occurring.

Assessment of skeletal maturity that performed in pediatric radiology involves rigorous examination of multiple factors and fundamental knowledge of the various process by which bone develop. As sex steroid levels rise during puberty, bone maturation accelerates.

As growth nears conclusion and attainment of adult height, bones begin to approach the size and shape of adult bones. The remaining cartilaginous portions of the epiphyses become thinner. As these cartilaginous zones become obliterated, the epiphyses are said to be "closed" and no further lengthening of the bones will occur. A small amount of spinal growth concludes an adolescent's growth. Pediatric endocrinologists are the physicians who most commonly order and interpret bone age x-rays and evaluate children for advanced or delayed growth and physical development. An advanced bone age is common when a child has had prolonged elevation of sex steroid levels, as in precocious puberty or congenital adrenal hyperplasia. The bone age is often marginally advanced with premature adrenarche, when a child is overweight from a young age or when a child has lipodystrophy. Bone age may be significantly advanced in genetic overgrowth syndromes, such as Soto's syndrome, Beckwith-Weidman syndrome and Marshall-Smith syndrome.⁽³⁾

Radial Bone

Anatomical Features: The radius is situated on the lateral side of the ulna, which exceeds it in length and size. Its upper end is small, and forms only a small part of the elbow-joint; but its lower end is large, and forms the chief part of the wrist-joint. It is a long bone, prismatic in form and slightly curved longitudinally. It has a body and two extremities. The upper extremity presents a head, neck, and tuberosity. The head is of a cylindrical form, and on its upper surface is a shallow cup or fovea for articulation with the capitulum of the humerus. The circumference of the head is smooth; it is broad medially where it articulates with the radial notch of the ulna, narrow in the rest of its extent, which is embraced by the annular ligament. The head is supported on a round, smooth, and constricted portion called the neck, on the back of which is a slight ridge for the insertion of part of the Supinator. Beneath the neck, on the medial side, is an eminence, the radial tuberosity; its surface is divided into a posterior, rough portion, for the insertion of the tendon of the Biceps brachii, and an anterior, smooth portion, on which a bursa is interposed between the tendon and the bone.

The body is prismoid in form, narrower above than below and slightly curved, so as to be convex lateral ward. It presents three borders and three surfaces. The volar border (*Margo volssaris*; anterior border) extends from the lower part of the tuberosity above to the anterior part of the base of the styloid process below, and separates the volar from the lateral surface⁽⁴⁾. Its upper third is prominent, and from its oblique direction has received the name of the oblique line of the radius; it gives origin to the Flexor digitorum sublimis and Flexor pollicis longus; the surface above the line gives insertion to part of the Supinator. The middle third of the volar border is indistinct and rounded. The lower fourth is prominent, and gives insertion to the Pronator quadratus, and attachment to the dorsal carpal ligament; it ends in a small tubercle, into which the tendon of the Brachioradialis is inserted. The dorsal border (*margo dorsalis*; posterior border) begins above at the back of the neck, and ends below at the posterior part of the base of the styloid process; it separates the posterior from the lateral surface. It is indistinct above and below, but well-marked in the middle third of the bone. The interosseous crest (*crista interossea*; internal or interosseous border) begins above, at the back part of the tuberosity, and its upper part is rounded and indistinct; it becomes sharp and prominent as it descends, and at its lower part divides into two ridges which are continued to the anterior and posterior margins of the ulnar notch. To the posterior of the two ridges the lower part of the interosseous membrane is attached, while the triangular surface between the ridges gives insertion to part of the Pronator quadratus. This crest separates the volar from the dorsal surface, and gives attachment to the interosseous membrane. The volar surface (*facies volaris*; anterior surface) is concave in its upper three-fourths, and gives origin to the Flexor pollicis longus; it is broad and flat in its lower fourth, and affords insertion to the Pronator quadratus⁽⁴⁾. A prominent ridge limits the insertion of the Pronator quadratus below, and between this and the inferior border is a triangular rough surface for the attachment of the volar radiocarpal ligament. At the junction of the upper and middle thirds of the volar surface is the nutrient foramen, which is directed obliquely upward. The dorsal surface (*facies dorsalis*; posterior surface) is convex, and smooth in the upper third of its extent, and

covered by the Supinator. Its middle third is broad, slightly concave, and gives origin to the Abductor pollicis longus above, and the Extensor pollicis brevis below. Its lower third is broad, convex, and covered by the tendons of the muscles which subsequently run in the grooves on the lower end of the bone.

The lateral surface (facies lateralis; external surface) is convex throughout its entire extent. Its upper third gives insertion to the Supinator. About its center is a rough ridge, for the insertion of the Pronator teres. Its lower part is narrow, and covered by the tendons of the Abductor pollicis longus and Extensor pollicis brevis. The lower extremity is large, of quadrilateral form, and provided with two articular surfaces—one below, for the carpus, and another at the medial side, for the ulna. The carpal articular surface is triangular, concave, smooth, and divided by a slight antero-posterior ridge into two parts. Of these, the lateral, triangular, articulates with the navicular bone; the medial, quadrilateral, with the lunate bone. The articular surface for the ulna is called the ulnar notch (sigmoid cavity) of the radius; it is narrow, concave, smooth, and articulates with the head of the ulna. These two articular surfaces are separated by a prominent ridge, to which the base of the triangular articular disk is attached; this disk separates the wrist-joint from the distal radioulnar articulation⁽⁴⁾. This end of the bone has three non-articular surfaces—volar, dorsal, and lateral. The volar surface, rough and irregular, affords attachment to the volar radiocarpal ligament. The dorsal surface is convex, affords attachment to the dorsal radiocarpal ligament, and is marked by three grooves. Enumerated from the lateral side, the first groove is broad, but shallow, and subdivided into two by a slight ridge; the lateral of these two transmits the tendon of the Extensor carpi radialis longus, the medial the tendon of the Extensor carpi radialis brevis. The second is deep but narrow, and bounded laterally by a sharply defined ridge; it is directed obliquely from above downward and lateralward, and transmits the tendon of the Extensor pollicis longus. The third is broad, for the passage of the tendons of the Extensor indicis proprius and Extensor digitorum communis. The lateral surface is prolonged obliquely downward into a strong, conical projection, the styloid process, which gives attachment by its base to the tendon of the Brachioradialis, and by its apex to the radial collateral ligament of the wrist-joint. The lateral surface of this process is marked by a flat groove, for the tendons of the Abductor pollicis longus and Extensor pollicis brevis. The long narrow medullary cavity is enclosed in a strong wall of compact tissue which is thickest along the interosseous border and thinnest at the extremities except over the cup-shaped articular surface (fovea) of the head where it is thickened. The trabeculae of the spongy tissue are somewhat arched at the upper end and pass upward from the compact layer of the shaft to the fovea capituli; they are crossed by others parallel to the surface of the fovea. The arrangement at the lower end is somewhat similar.⁽⁴⁾

Ossification of the Radius: Cartilaginous model of long bones in fetus undergoes series of changes occurring in definite sequence that will ultimately transform this minute structure into an adult bone many times its size; covering cells of the cartilage model, the perichondrium, change from cartilage-producing cells to bone-forming cells, osteoblasts, in middle portion of shaft. The newly created periosteum forms a thin shell of bone about middle of cartilage model; cells w/in center of model hypertrophy, and vessels grow into shaft from surface; as vessels come into contact w/ cartilage cells, these cells are destroyed and replaced by bone; bone nucleus spreads lengthwise in both directions from middle of model, until bone reaches level of future epiphyseal plate. The radius is ossified from three centers: one for the body, and one for either extremity. That for the body makes its appearance near the center of the bone, during the eighth week of fetal life. About the end of the second year, ossification commences in the lower end; and at the fifth year, in the upper end. The upper epiphysis fuses with the body at the age of seventeen or eighteen years, the lower about the age of twenty. An additional center sometimes found in the radial tuberosity, appears about the fourteenth or fifteenth year⁽⁴⁾.

Comparative Studies

Radiological bone age assessment by appearance of ossification centers in pediatric: This research studied the relationship of the endocrine glands to skeletal growth and maturation is. He stated that Roentgen examination of the growing skeleton may give valuable information concerning thyroid, pituitary and gonadal disturbances. They all causes generalized skeletal age abnormality. Delay in appearance or fusion or

retardation of epiphyseal centers may result from deficient secretion by one or more of these glands. Hyper secretion may accelerate this process. His study carried out in 507 children, 268 males and 239 females between age group of 1-12 years. He compares study result with Greulich-Pyle standard and also with other Indian studies. He found that the appearance of ossification centres in >50% of children for Head of radius are at the age of 7-8 years in Males and at 5-6 years in Females. 100% appearance is seen at 9-10 years in Males and at 7-8 years in Females. And appearance of ossification centres in >50% of children for Medial epicondyle is at the age of 8-9 years in Males and at 4-5 years in Females.⁽⁵⁾ Bone age maturation and growth velocity were analyzed longitudinally by the TW2 RUS method standardized for Japanese children in 45 GH-treated boys with idiopathic GH deficiency (GHD).

The patients were divided into three groups: Group I consisted of four isolated GHD patients who underwent spontaneous puberty without gonadotropin suppression treatment (GST) and had a mean final height of 151.9 cm; Group II consisted of 24 GHD patients with associated gonadotropin deficiency who received sex hormone replacement treatment (GRT) and had a mean final height of 165.3 cm; Group III consisted of 17 isolated GHD patients who underwent spontaneous puberty and had a mean final height of 158.3 cm after being treated with combined GH and GST. Bone age matured along with chronological age in Group I, whereas bone age in Group II decelerated significantly after a bone age of 12 years and did not reach a bone age of 14 years. Bone age maturation in Group III showed an intermediate pattern between Groups I and II; bone age decelerated significantly after a bone age of 12 years but mean bone age advanced beyond a bone age of 14 years. Height velocity in Group I during GH treatment decelerated rapidly after the pubertal growth spurt, as usually seen in normal puberty. A definite pubertal growth spurt was not observed in the height velocity of Group II during GH treatment before receiving GRT; the mean height velocity gradually declined, remaining at 3.5-4.5 cm/year even after 18 years. Mean height velocity in Group III during GH treatment and GST showed a similar tendency as Group II, but it declined more rapidly. Since a growth velocity of around 3 cm/year was preserved with GH treatment despite the decline in growth velocity, the slower the advance of bone age, the longer the treatment period and, therefore, the taller the final height achieved by GST compared to Group I. It is recommended to start GST at a bone age between 11.5 years and 13 years. The timing, namely when to start GRT in GHD with gonadotropin deficiency or when to stop GST in isolated GHD, can be estimated according to the patient's desired final height and bone age-growth potential.⁽⁶⁾

Ossification centers at the elbow joint in Bengali girls: This research studied the time of ossification of the elbow in Bengali girls. The study carried out in 313 healthy school girls from 6 to 16 years of age from middle income Bengali families. Radiological study of norms of skeletal maturity at the elbow joint.

The age of appearance and fusion of the four centers of the epiphyses at the lower end of the humerus and the centers for the head of the radius and top of the ulnar olecranon is reported.

The 11th year seems to be an important landmark in growth when fusion commences at a rapid pace. By the thirteenth years the acceleration in growth is nearly complete. The skeletal maturity of the three long bones around the elbow joint was completed by the 16th years⁽⁷⁾.

Accuracy of the Sauvegrain method in determining skeletal age during puberty: For the assessment of skeletal age from radiographs of the elbow, they stated that it is useful during the two years of the pubertal growth spurt. The Sauvegrain method uses four anatomical landmarks of the elbow the lateral condyle, trochlea, olecranon apophysis, and proximal radial epiphysis. It is based on a 27-point scoring system. The scores for these structures are summed, and a total score is determined. A graph is then used to determine the skeletal age. The method was evaluated by three independent observers who used it to assess skeletal age on anteroposterior and lateral radiographs of the left elbow of sixty boys and sixty girls and compared the results with assessments made with use of the Greulich and Pyle atlas on posteroanterior radiographs of the left hand and wrist. Skeletal age determinations were performed twice by each observer at a four-week interval. They found that skeletal age determination from radiographs of the elbow was more precise because a clear semiannual age determination was possible.⁽⁸⁾

Time of fusion of epiphyses at the elbow and wrist joints in girls of northwest India: The time of fusion of epiphyses at the elbow and wrist joints in girls of northwest India by using the radiograph of wrist and elbow and he found that a radiological examination of both elbows and wrists of 149 Northwest Indian schoolgirls between the ages of 11 and 19 years, of middle socio-economic status, was undertaken to determine the time of fusion of the epiphyses with the metaphyses of the medial epicondyle of the humerus, the proximal end of the radius and the distal ends of both radius and ulna. The data were subjected to discriminate function tests as well as sensitivity and specificity tests.

If the epiphysis of the medial epicondyle of the humerus or that of the head of the radius has not fused with metaphysis completely, the age of the girl would be < 16 years. However, the age of the girl should be > 16 years if the distal epiphyses of the radius and the ulna show complete fusion with their respective metaphyses.

Discriminate function tests show that 91.95% of girls can be correctly classified as being above or below the age of 16 years⁽⁹⁾.

Gender-specific pattern differences of the ossification centers in the pediatric elbow: Study differences of the ossification centers in the pediatric elbow to center both appears and fuses, and also to identify differences between genders. This study included 412 sets of radiographs of children's elbows that were analyzed prospectively by a single experienced pediatric radiologist. The presence as well as state of fusion of each ossification center was noted. The ages of the children ranged from 2 months to 17 years. They found that in girls the radial head and medial epicondyle appeared at the same age. In boys there was a trend towards the radial head appearing earlier than the medial epicondyle. There was no statistically significant difference between the age at which the trochlea and olecranon appeared. Their results demonstrate a statistically significant difference between genders in both appearance and fusion. All centers both appeared and fused earlier in girls, with the exception of the appearance of the capitellum. The sequence of appearance and fusion was similar between genders.⁽¹⁰⁾

The timing of ossification center: The Pediatric Orthopedic Society of North America studied the timing of ossification centers. They found that ossification center for the capitellum appears by about 8 months, the radial head at about age 3-4, the medial epicondyle at about age 5, the trochlea at about age 7, the olecranon at about age 9, and the lateral epicondyle at about age 11. The eponym for remembering these ossification centers is CRITOE, designating the order of appearance is Capitellum, Radial head, Internal (medial) epicondyle, Trochlea, Olecranon, and External (lateral) epicondyle. If one calculates the capitellum ossifies by age 1; and adds 2 years for the appearance of each successive ossification center, the scheme is not too far from accurate⁽¹¹⁾.

Determination of Age of Majority of Manipuri Girls from the Radiological Examination of the Joints: Determination of age of majority of manipuri girls from the radiological examination of the joints. 50 Manipuri Meitei girls of 18 years of age, born and brought up in imphal, were x-rayed at the elbow, knee, wrist joints and the pelvis. the epiphyses studied at these joints the age determination from radiological examination of joints result in that degree of fusion of the epiphyses around the different joints was completed by the age of 18 years.(12)

Estimation of age from 13 to 21 years: Estimation of age from 13 to 21 years in Jaipur, Rajasthan he found that Epiphysis union in girls occurs about 6 month earlier than in boys in Jaipur. Epiphyseal union in boys and girls of Jaipur were not the same as observed in other parts of the country and in different countries. That in persons living at higher attitude the union of epiphysis occurs later than people living in Jaipur.

Materials and Methods

Study Design: Cross -sectional descriptive Hospital based study, it is comparative study of a sample of 40 female Sudanese children and adolescents aged between 1 and 19 years. The children were from all social classes. The study is focused on analyzing the time of appearance and fusion of the ossification centers of the upper end of the radius at the elbow joint.

Study area: Khartoum state, the radiographs collected from Gafar Ibn Auf Children's hospital, Omdurman teaching hospital, Bahri teaching hospital and Khartoum educational hospital.

Study Population

1. Sudanese female of various ages (age from 1 to 19 years).
2. The children were from all social classes, with variable socioeconomic status and healthy in nutritional condition at the time of radiograph.

Data Collection: The data collected by group formed by six researchers because they work in same area, the data chosen depend on age, sex, health status, and socio-economic levels, the researchers collected 40 female radiographs and 5 samples were excluded based on exclusion criteria.

Sample Size: The radiographs were 40 in numbers, 35 were suitable for studying and only 5 were excluded.

Inclusion Criteria

1. Age from 1 to 19 years females.
2. X-rays of children with good position, adequate quality and adequate information of chronological age and sex.
3. Patients with disease not affecting bone growth.

Exclusion Criteria:

1. Age more than 19 years.
2. Children with illness that affected bone age e.g. diabetes, sickle cell anemia, rickets, etc.
3. Children, who had congenital, endocrinological or other serious disease.
4. X-rays of children with poor position, inadequate quality or inadequate information of chronological age and sex.

Data Collection Tools: X-rays images of the upper end of the radius at the elbow joint in the supine position. X-rays were taken by Shimadzu x-ray system and Toshiba.

All the samples were already complaining of upper limb pain and were referred to X-ray department.

Radiological Specification

1. X ray in the right and left elbow –AP & lateral view
2. KV40-42 (centered at elbow)
3. mAs 3.8-4.6
4. Tube distance: 36 inches
5. Films size: B & C

Data Analysis: Statistical analysis was performed using statistical program: SPSS.

RESULTS

Data Analysis: The numbers of the radiographs were 40, 35 of them were suitable for analysis, while 5 were excluded due to different pathological and congenital causes. The data were classified into four age groups according to stage of ossification of O.Cs:

1. Group 1 describes the non-ossified O.Cs. 1 to 2 years include 4 samples.
2. Group 2 describes the partially ossified O.Cs. 3 to 7 years include 23 samples
3. group 3 describes the fully ossified O.Cs. 8 to 13 include 6 samples
4. group 4 describes the complete ossified O.Cs. 13 to 19 include 2 samples.

Stage-1: Non-Ossified O.cs.

- A. The mean age of non-ossified O.Cs of the upper end of the radius in female is 1.75 year.
- B. The minimum age of non-ossified O.Cs of the upper end of the radius in female is 1 year, while the maximum age is 2 years (Table-1).

Table-1: O.Cs of the Upper End of the Radius: Non-Ossified

Gender	N	Minimum Age	Maximum Age	Mean Age	Std. Deviation
Female	4	1	2	1.75	.500

Stage-2: Partial-Ossified

- The mean age of partial-ossified O.Cs of the upper end of the radius in female is 5.26 year
- The minimum age of partial-ossified O.Cs of the upper end of the radius in female is 3 years, while the maximum age is 7 years (Table-2)

Table-2: O.Cs of the Upper End of the Radius: Partial-Ossified

Gender	N	Minimum Age	Maximum Age	Mean Age	Std. Deviation
Female	23	3	7	5.26	1.356

Stage-3: Full-Ossified

- The mean age of full-ossified O.Cs of the upper end of the radius in female is 11.83 year.
- The minimum age of full-ossified O.Cs of the upper end of the radius in female is 9 year, while the maximum age is 13 years (Table-3).

Table-3: O.Cs of the Upper End of the Radius: Full-Ossified

Gender	N	Minimum Age	Maximum Age	Mean Age	Std. Deviation
Female	6	9	13	11.83	1.602

Stage-4: Complete-Ossified

- The mean age of complete-ossified O.Cs of the upper end of the radius in female is 15.50 year
- The minimum age of complete-ossified O.Cs of the upper end of the radius in female is 14 year, while the maximum age is 17 years (Table-4)

Table-4: O.Cs of the Upper End of the Radius: Complete-Ossified

Gender	N	Minimum Age	Maximum Age	Mean Age	Std. Deviation
Female	2	14	17	15.50	2.121

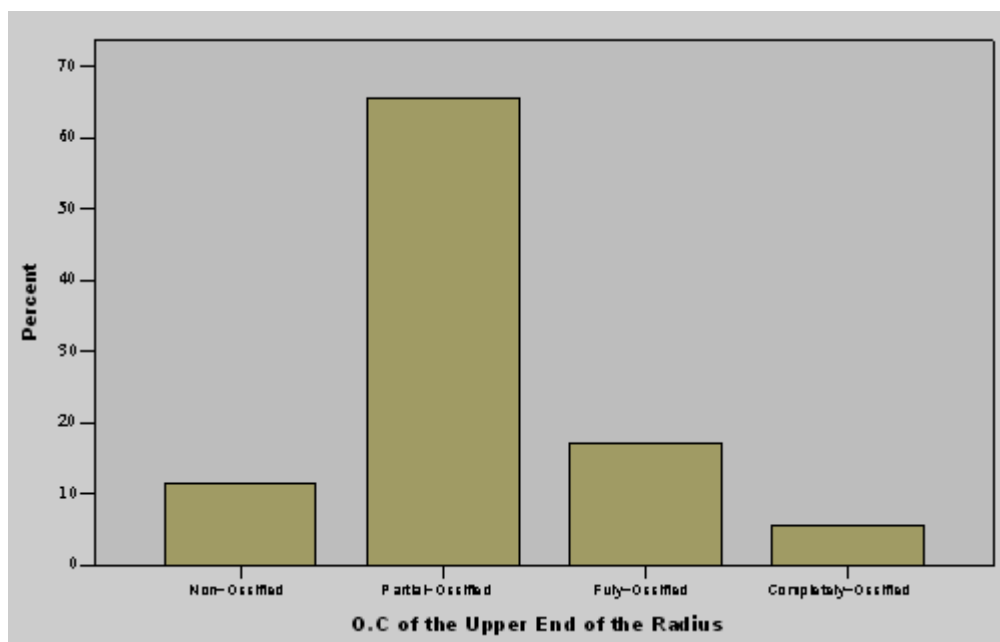


Figure-1: O.Cs of the Upper end of the Radius in Female

DISCUSSION

This comparative study of a sample of 40 female Sudanese children and adolescents aged between 1 and 19 years. The children were from all social classes. The study is focused on analyzing the time of appearance and fusion of the ossification centers of the upper end of the radius at the elbow joint. The study aimed to determine the suitable ages of healthy female Sudanese girls, the ages that indicated the time of maturation of the upper radial bone. The study was carried on in Khartoum state, by collecting radial upper end radiographic images.

The study stated that ossification centers of the bones around the elbow joint in Sudanese children are not widely different when compared to the atlas of Schinizand and Baenisch there is slight difference between bone age and chronological age so I suggest that stander atlas of Schinizand and Baenisch can be used to determine the age of Sudanese children with reservation butting in consideration the slight variation.

The slight difference between our study and previous studies may be due many factors like racial, genetic, socio economic, nutritional and climate factors. These factors should be considered in determination of bone age in Sudanese. Study showed that the ossification center of the upper end of the radius appears during the fifth year in female and it joined the shaft during the fifteenth years in female.

Limitations of the study:

1. All participants came with an orthopedic problem and obtained from screening.
2. Sample size is small (only 40 female) so the results may not be generalized.
3. Also ethnic groups were not considered in sampling

Conclusion and Recommendation

Conclusion: The study showed that the ossification center of the upper end of the radius appears during the fifth year in female and it joined the shaft during the fifteenth years in female. This not differs from the findings of the Schiniz and Baenisch which stated that the ossification center appears during the sixth or Seventh years In a very small percentage appear at eight Years. It joins the shaft in the fourteenth year in female, but in male during the eighteenth or nineteenth year.

Generally the ossification centers of the bones around the elbow joint in sudanese children is similar to that of Schinizand Baenisch particularly in the upper end of radius, lateral epicondyle and olecranon process but there is slight difference in capitulum and great difference in the medial epicondyle.

Recommendation: The study recommended the physician to use the elbow in determination of bone age because it is more accurate.

1. The study recommended researchers to do comparative studies between males and females that concerning about the estimation of ages by using the upper end the radius
2. The study is carried on 40 girls, so I recommend for large volume for new studies, so we can reaches precise results.
3. The study is carried on individuals those their ages between one year to nineteen, so recommended for new studies concerning about elder ages.

References

- [1]. Henry Gray (1821–1865). Anatomy of the Human Body- Skeleton – Radius- 1918
- [2]. From the moment of birth until the time one has grown up, bones go through a set a characteristic changes. Therefore the skeletal maturity, or bone age, can be estimated from radiographs of specific bones in the human body.Nimbi tg, radiological bone age assessment by appearance of ossification centers in pediatric, journal of forensic medicine and toxicology, 2008; 9, 30-32.
- [3]. Michel s et al. bone age maturation and bone age at the elbow: journal of bone and joint surgery, 2008, 90-b, 237-238.
- [4]. Cameriere R, Ferrante L.- Age estimation in children by measurement of carpals and epiphyses of radius and ulna and open apices in teeth-Institute of Legal Medicine, University of Macerata, Via D. Minzoni 9, 62100 Macerata, Italy. r.cameriere@unimc.
- [5]. Nimbi tg, radiological bone age assessment by appearance of ossification centers in pediatric, journal of forensic medicine and toxicology, 2008; 9, 30-32.
- [6]. Satoh M, Tanaka T, Hibi I.-Analysis of bone age maturation and growth velocity in isolated growth hormone (GH) deficient boys with and without gonadal suppression treatment and in GH deficient boys with associated gonadotropin deficiency-1st Department of Pediatrics, Toho University School of Medicine, Tokyo, Japan.
- [7]. Gul kripalani et al, ossification centers at the elbow joint in bengali girls, indian journal of pediatrics, 1987, 54, 295-302.
- [8]. Alain diméglio et al. accuracy of the sauvegrain method in determining skeletal age during puberty. Journal of bone and joint surgery (american).2005; 87:1689-1696.
- [9]. Sahni d, jit i, time of fusion of epiphyses at the elbow and wrist joints in girls of northwest india, forensic sci int pubmed. 1995, 30, 47-55.
- [10]. Patel b et al, gender-specific pattern differences of the ossification centers in the pediatric elbow, pediatric radiology, 2009, 39:226-23
- [11]. The pediatric orthopedic society of north america (www.posna.org), the timing of ossification center, 2010.
- [12]. Th. Bijoy singh, determination of age of majority of manipuri girls from the radiological examination of the joints, medico-legal update 2007, 7, 4-6
- [13]. Sheetal, j. d.: estimation of age from 13 to 21 years,journal of forensic medicine & toxicology,1999:16,1.
- [14]. M. Niemeijer, B. van Ginneken, C. Maas, F.J.A. Beek, M.A. Viergever, "Assessing the Skeletal Age From a Hand Radiograph: Automating the Tanner-Whitehouse Method", in: SPIE Medical Imaging, Editor(s): M. Sonka, J.M. Fitzpatrick, SPIE, 2003, vol. 5032, pp. 1197-1205.

Appendix

Figure-1: Female 2Years

Non ossified O.cs of the upper end of the radius

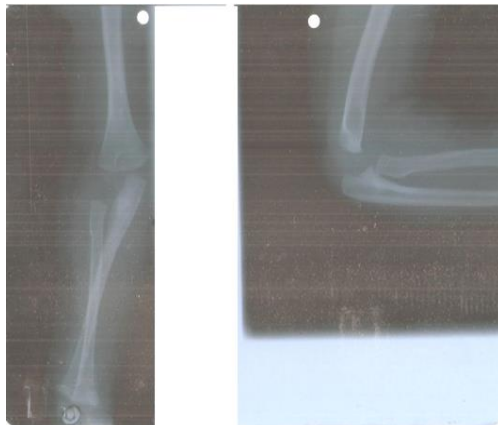

Figure-2: Female 4Years

Partial ossified O.cs of the upper end of the radius

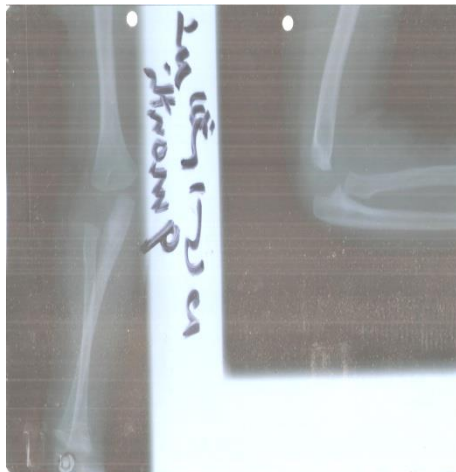

Figure-3: Female 13Years

Complete ossified O.cs of the upper end of the radius

